



PRESENTING CLINICAL SIGNS

DATE History: Presented for vomiting and lethargy that occurred in the middle of last night. Seems to be better this morning, but a new murmur was ausculted. Concern for possible syncopal episode.

2/25/22

ECHOCARDIOGRAPHIC FINDINGS

2D, M-mode, and Doppler study.

PERFORMED BY:

Dr. Meredith Swart

Left atrial size is normal. The mitral valve is normal. Left ventricular wall thickness is normal. Left ventricular internal dimensions are normal. Left ventricular systolic function is mildly hyperdynamic. The aorta and aortic valve are normal. Right atrial and right ventricular dimensions are normal. The tricuspid valve is normal. The pulmonary artery and pulmonic valve are normal. No shunting lesions are visualized. No pericardial effusion or cardiac masses are seen.

INTERPRETED BY

Keith Blass, DVM,
MS, DACVIM
(Cardiology)

LA – 22.2 mm
IVSd – 5.0 mm
LVPWd – 5.1 mm
LVIDd – 22.4 mm
LVIDs – 12.6 mm
FS – 43.8%
LVOT – 1.46 m/s
RVOT – 1.23 m/s

PATIENT

Doc Jordan

ASSESSMENT/RECOMMENDATIONS

SPECIES

Normal echocardiogram

Canine

This examination demonstrates no evidence of structural heart disease. While a definitive reason for Doc's murmur was not identified, it's likely that his murmur is functional/innocent in nature, as no flow abnormalities that could result in the development of a pathologic murmur are appreciated in the image set.

BREED

Dachshund Mix

No reason for syncope is seen in this exam, though, if an episode did occur, vasovagal syncope would be the most likely differential.

SEX

No therapy is recommended based on this exam.

MN

A recheck echocardiogram is recommended if the characteristics of Doc's murmur change, or if other new physical exam and/or clinical abnormalities suggestive of cardiac dysfunction develop.

AGE

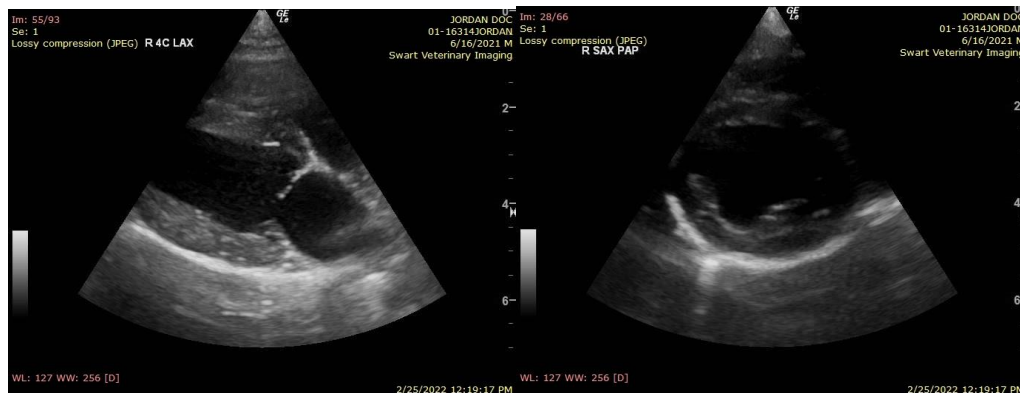
8 mo

WEIGHT

11 lb

HOSPITAL NAME

Swart Veterinary
Imaging



REFERRING VET

Dr. Swart

The information and recommendations provided are based on the images presented by the



DATE referring veterinarian. No evaluation can be communicated regarding pathology that was not visible in the image/video clips provided.

2/25/22 Thank you for this referral. If the clinical or image interpretation does not parallel your findings or if I can be of any further assistance please contact me.

PERFORMED BY: Keith Blass, DVM, MS, DACVIM (Cardiology)
KeithBlass@gmail.com
631-804-5754

Dr. Meredith Swart

INTERPRETED BY

Keith Blass, DVM,
MS, DACVIM
(Cardiology)

PATIENT

Doc Jordan

SPECIES

Canine

BREED

Dachshund Mix

SEX

MN

AGE

8 mo

WEIGHT

11 lb

HOSPITAL NAME

Swart Veterinary
Imaging

REFERRING VET

Dr. Swart